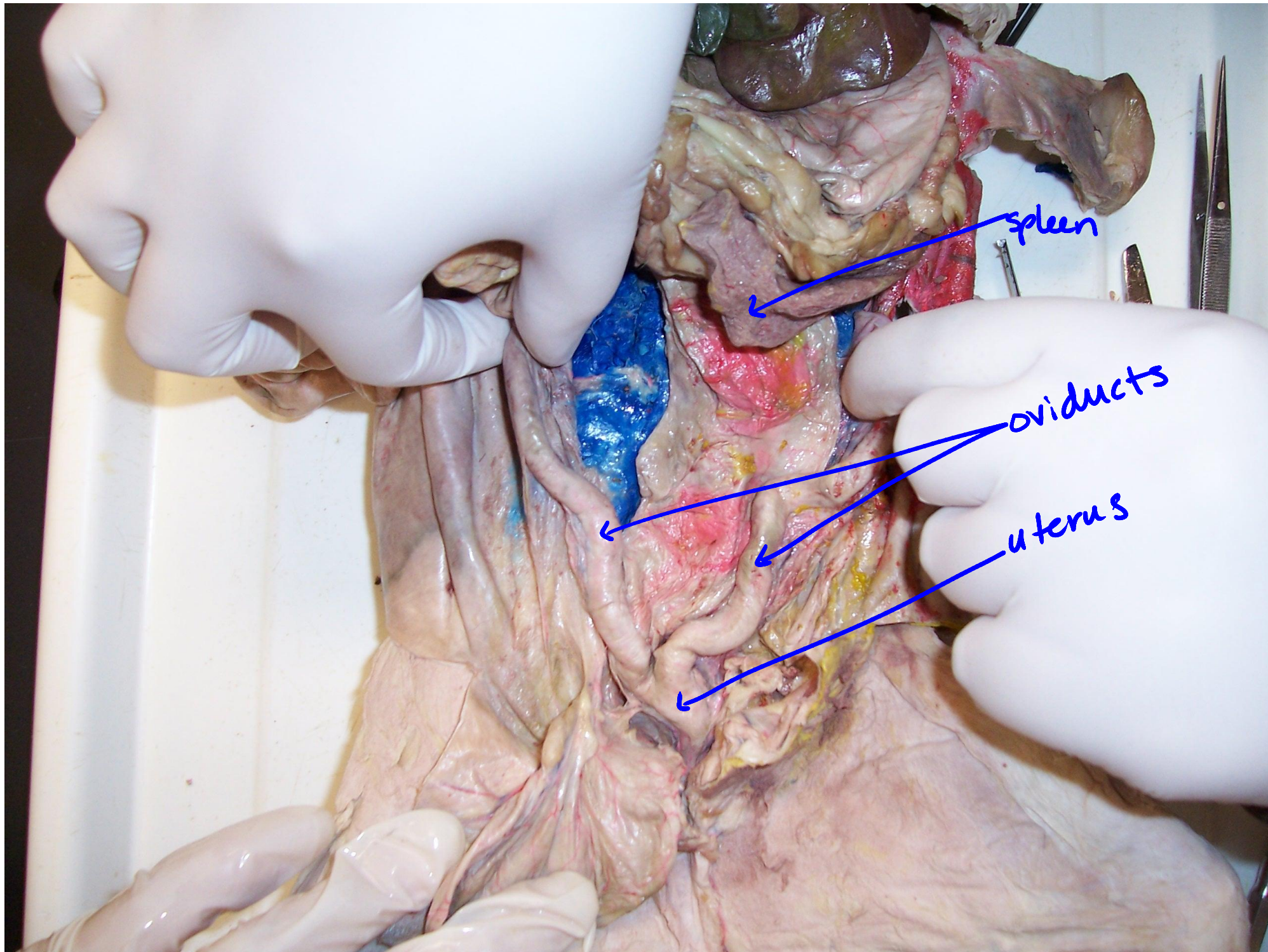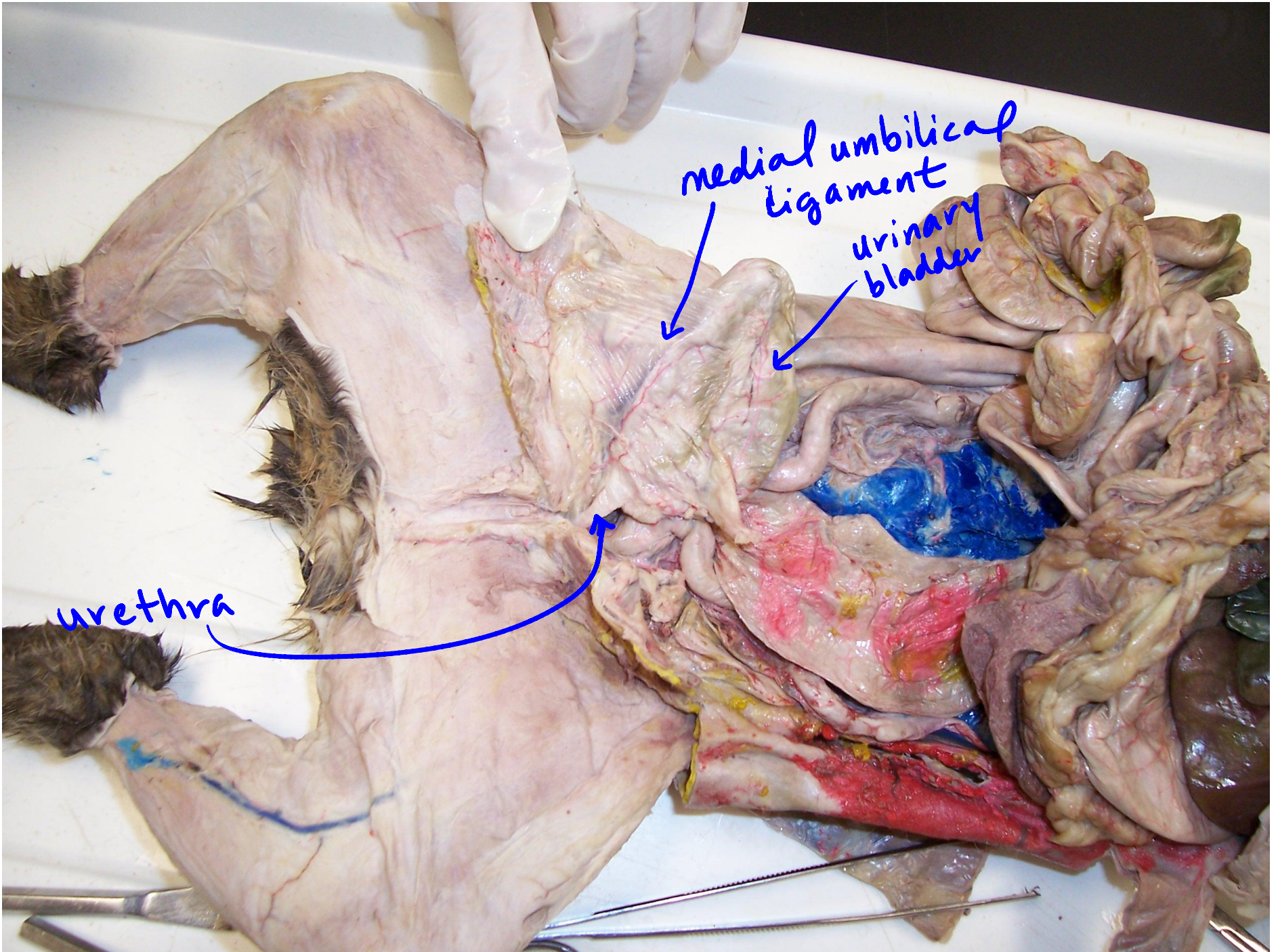


spleen

oviducts

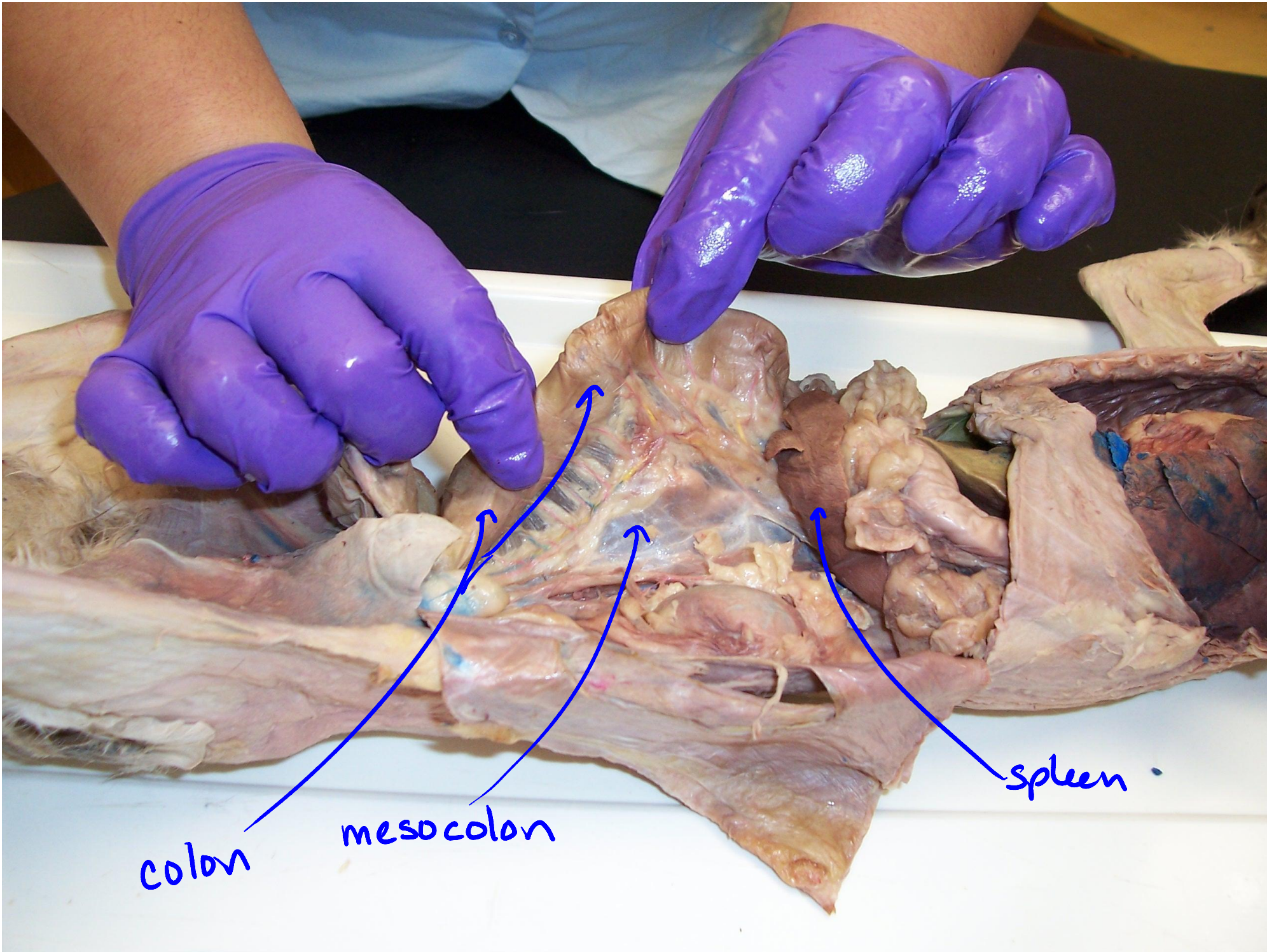
uterus



medial umbilical ligament

urinary bladder

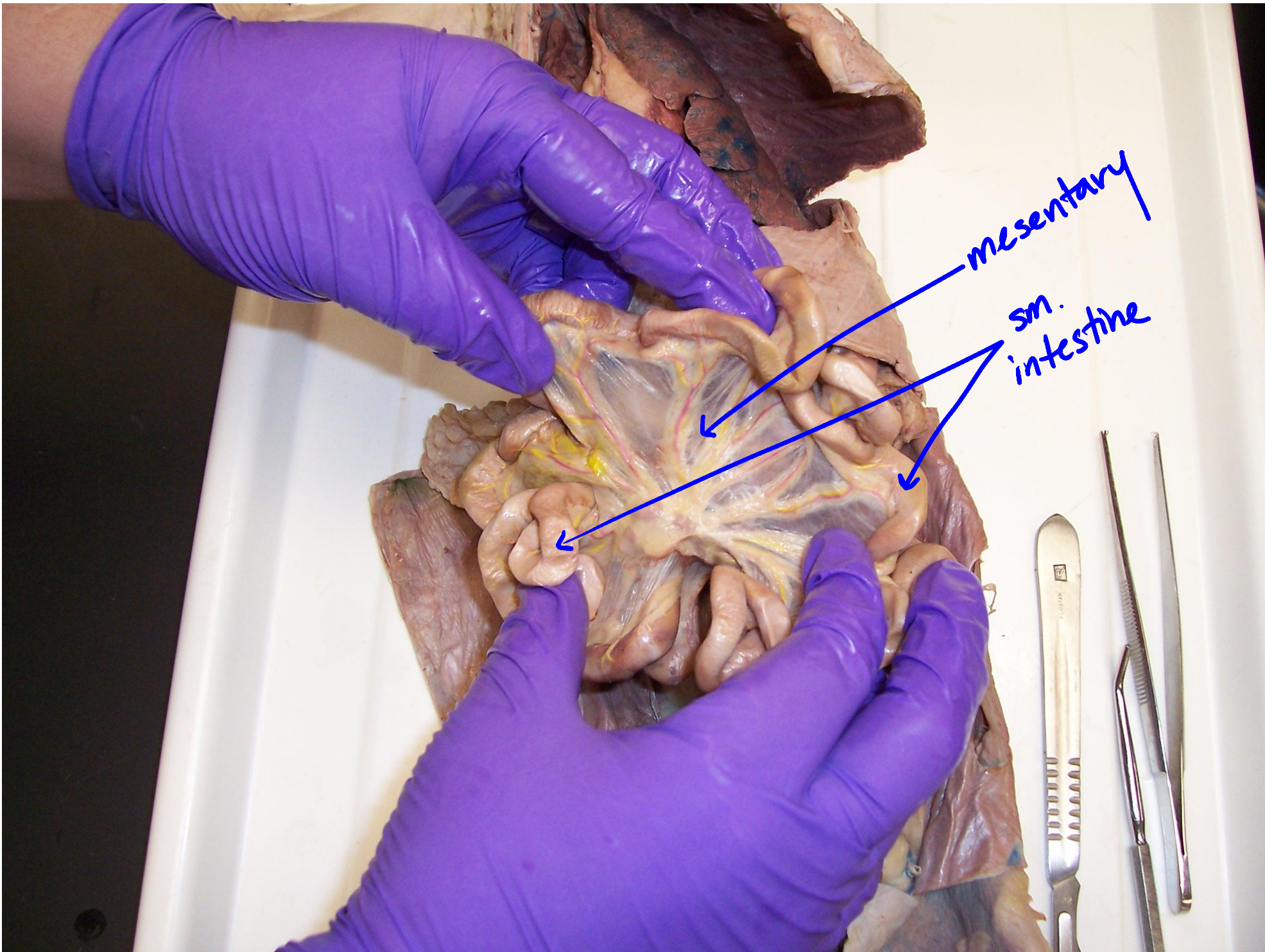
urethra



colon

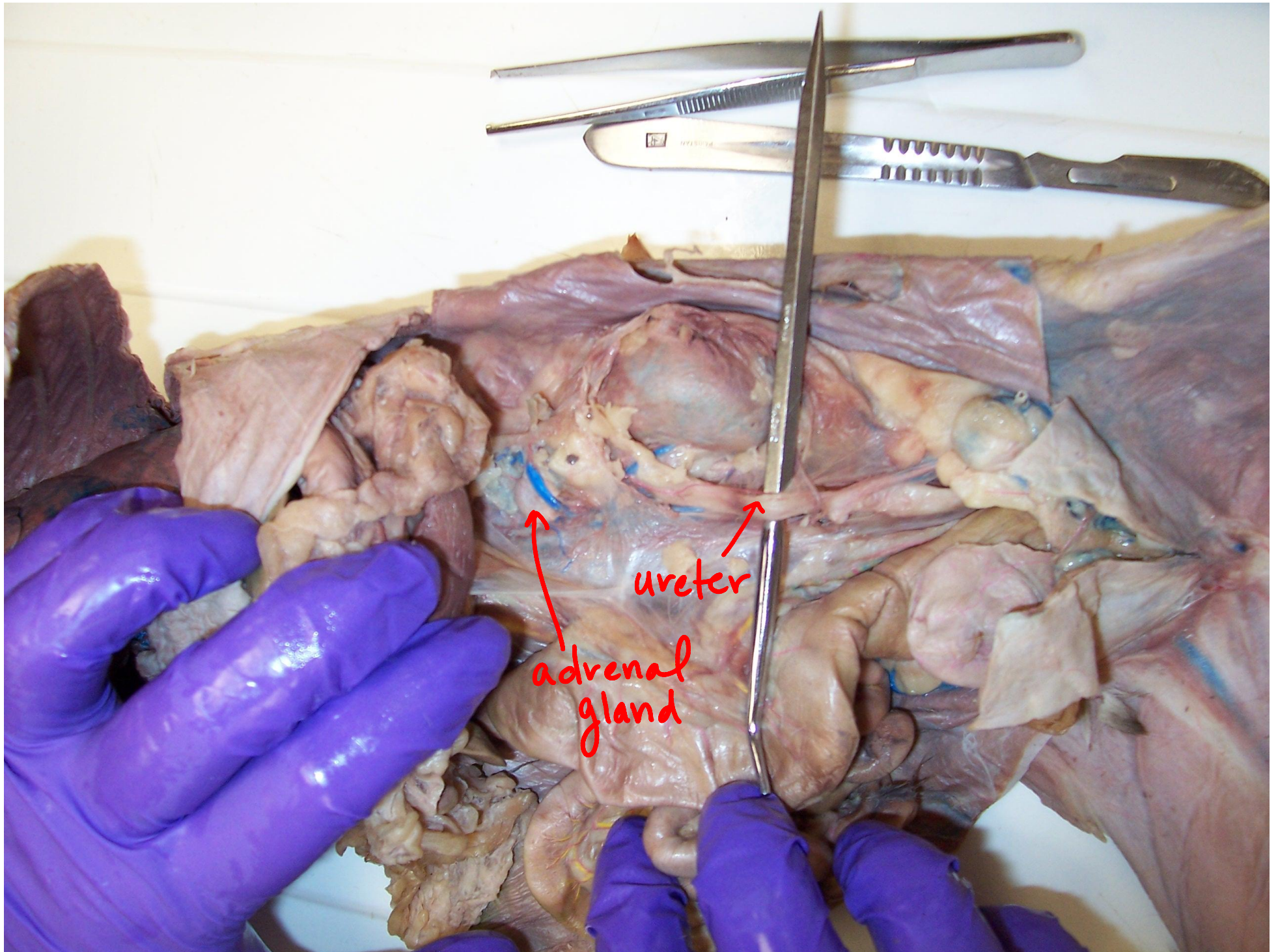
mesocolon

spleen



mesentery

sm.
intestine



adrenal
gland

ureter