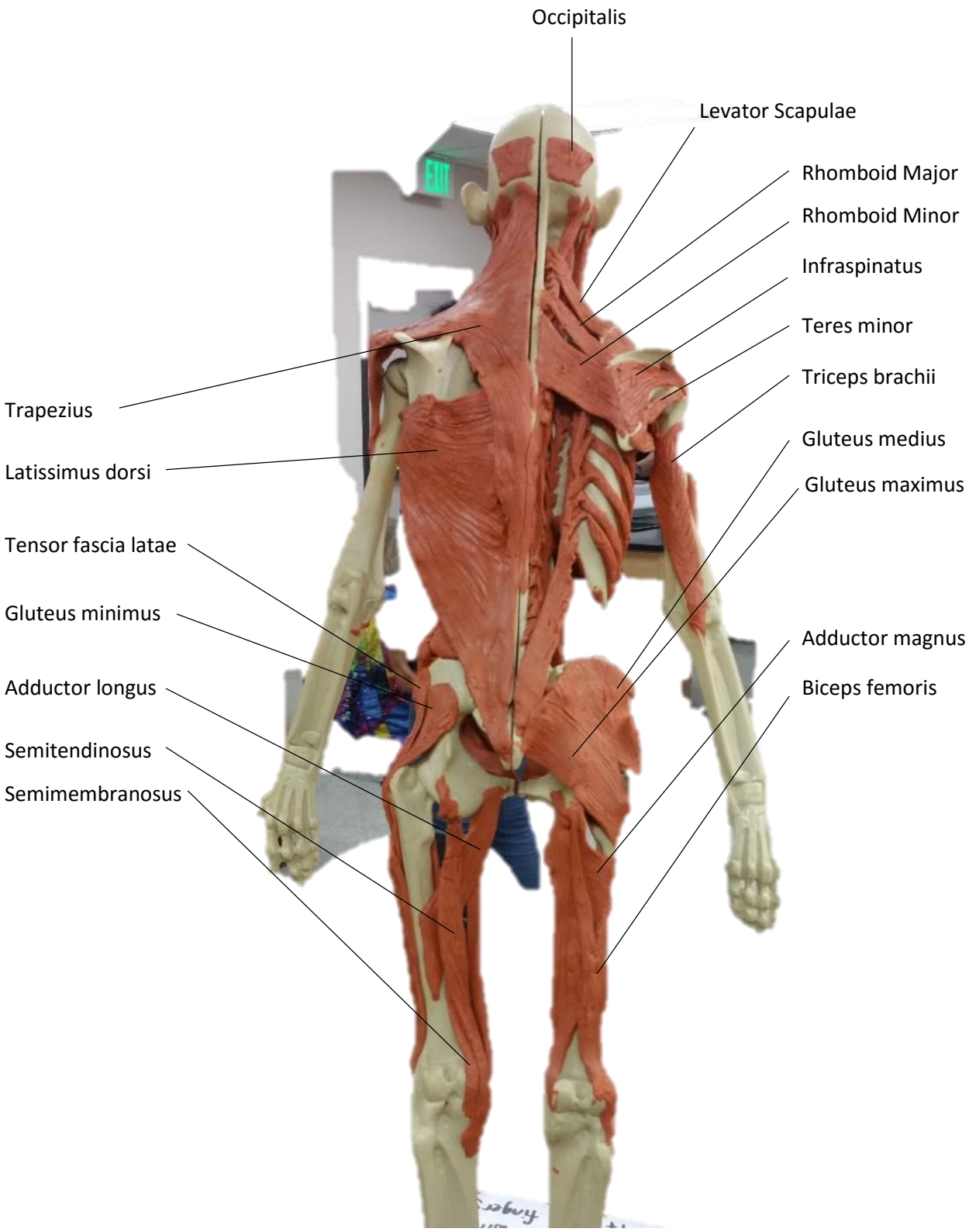
Occipitalis
Levator Scapulae
Rhomboid Major
Rhomboid Minor
Infraspinatus
Teres minor
Triceps brachii
Trapezius
Gluteus medius
Latissimus dorsi
Gluteus maximus
Tensor fascia latae
Gluteus minimus
Adductor magnus
Adductor longus
Biceps femoris
Semitendinosus
Semimembranosus
EXIT

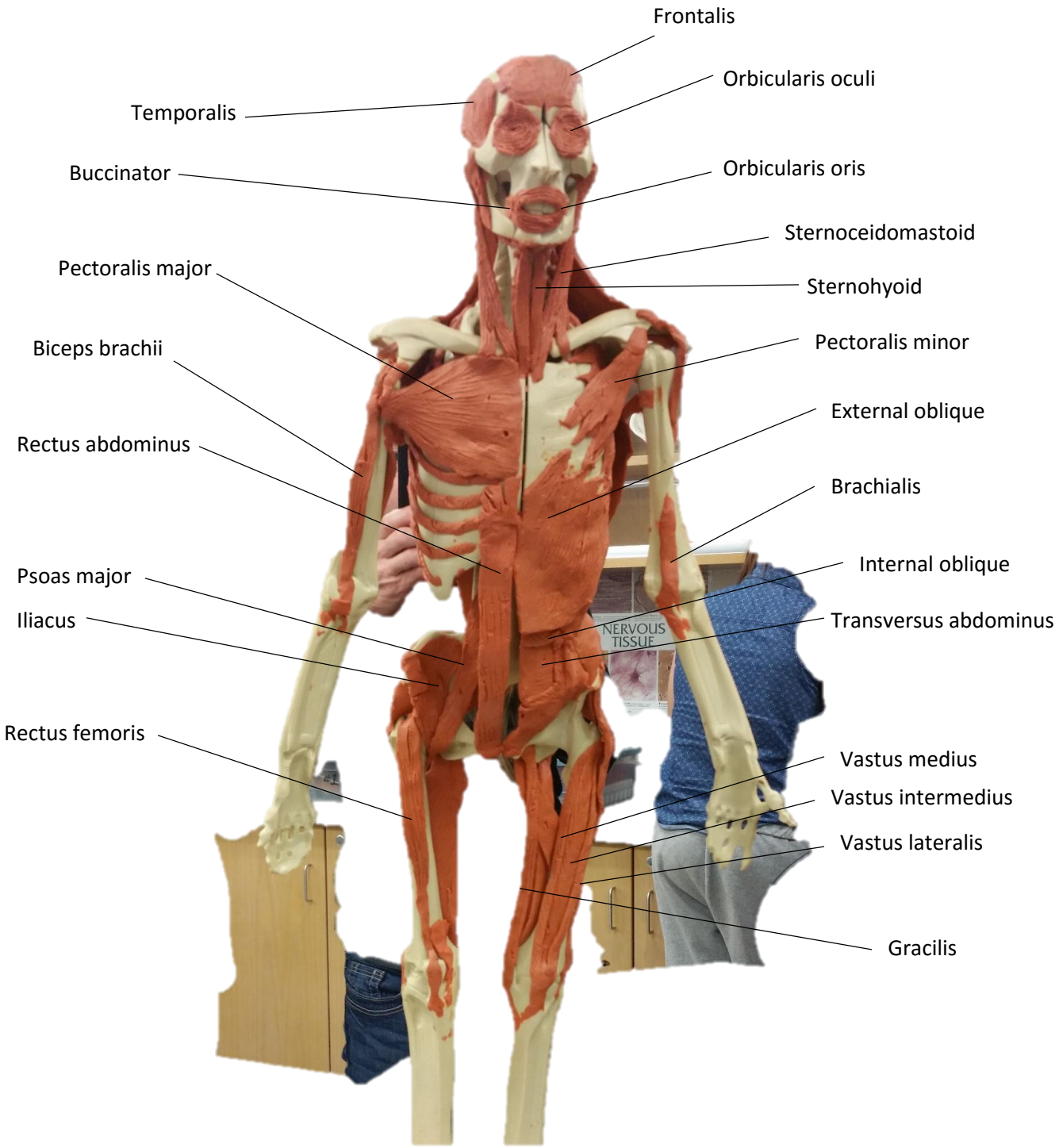
Frontalis
Orbicularis oculi
Temporalis
Buccinator
Orbicularis oris
Sternoceidomastoid
Pectoralis major
Sternohyoid
Biceps brachii
Pectoralis minor
External oblique
Rectus abdominus
Brachialis
Internal oblique
Psoas major
Transversus abdominus
Iliacus
NERVOUS TISSUE
Rectus femoris
Vastus medius
Vastus intermedius
Vastus lateralis
Gracilis